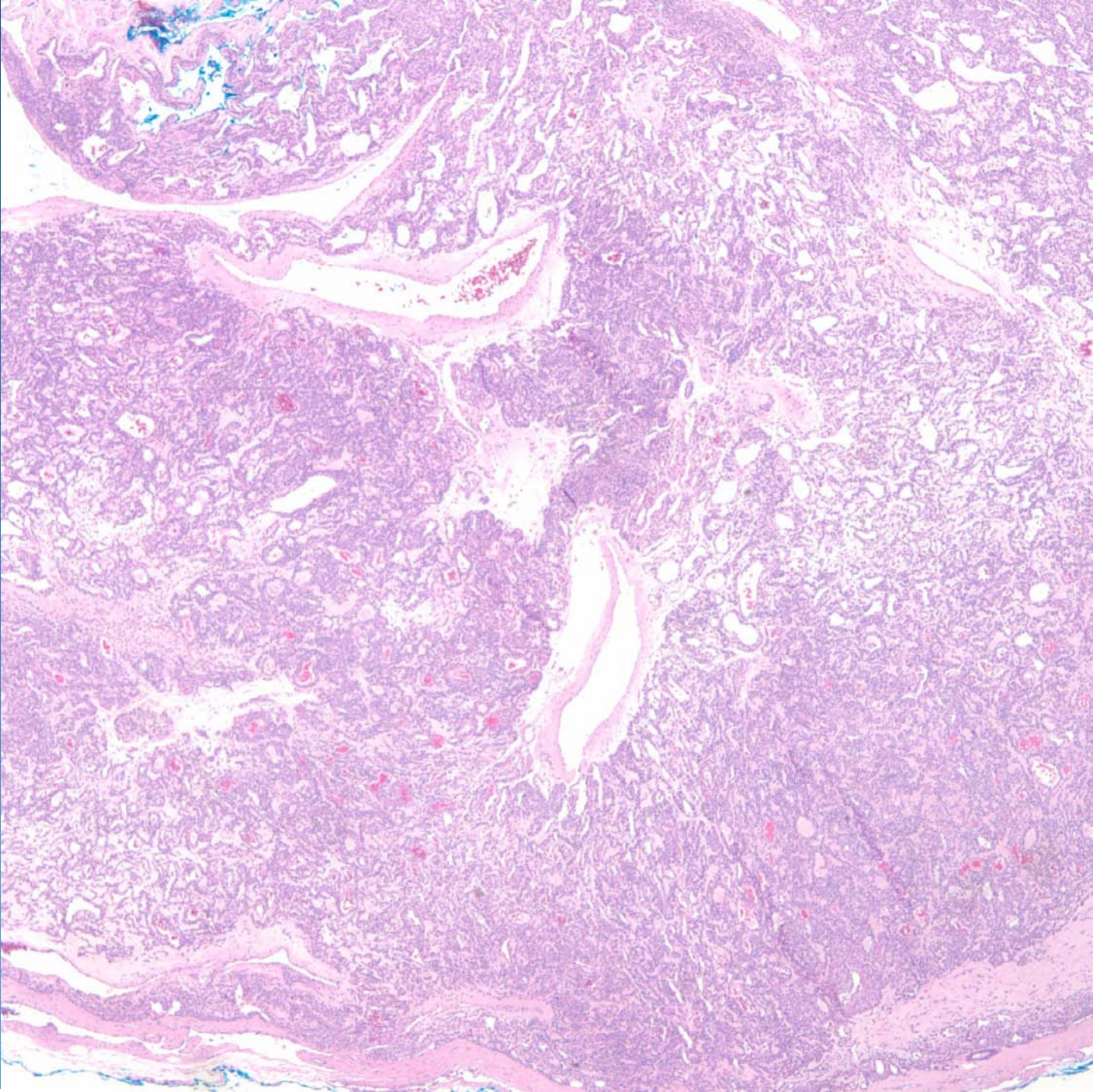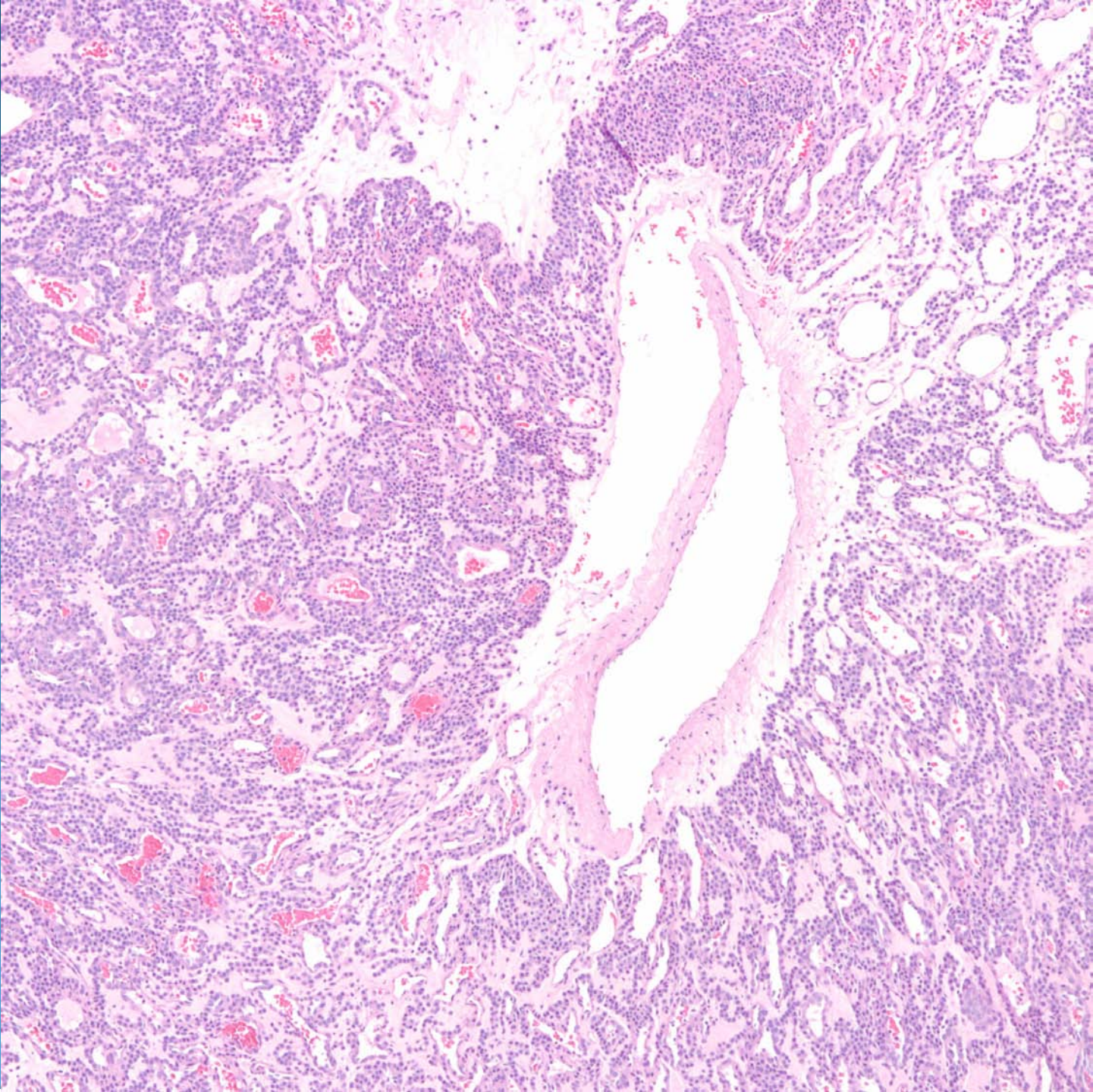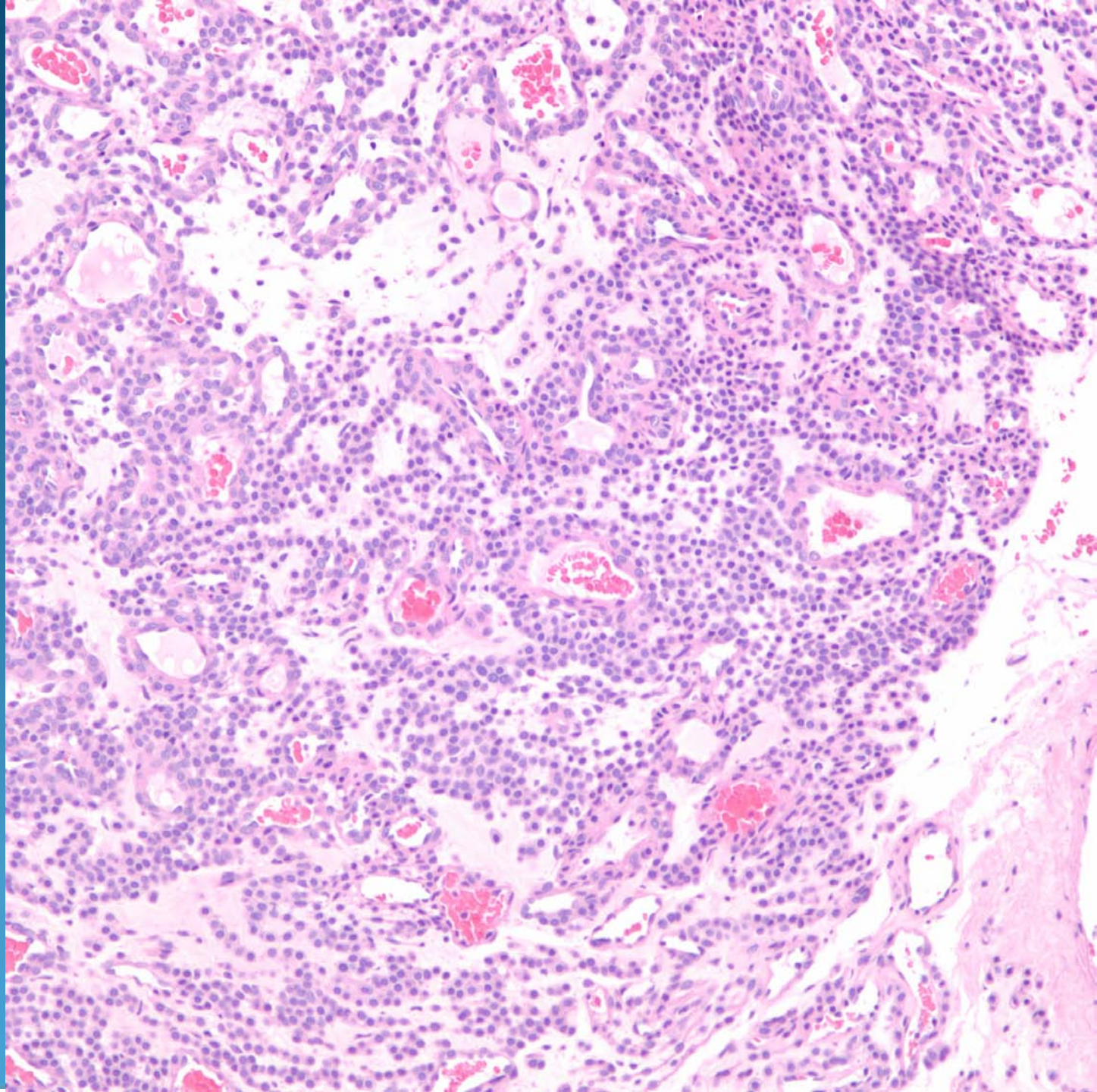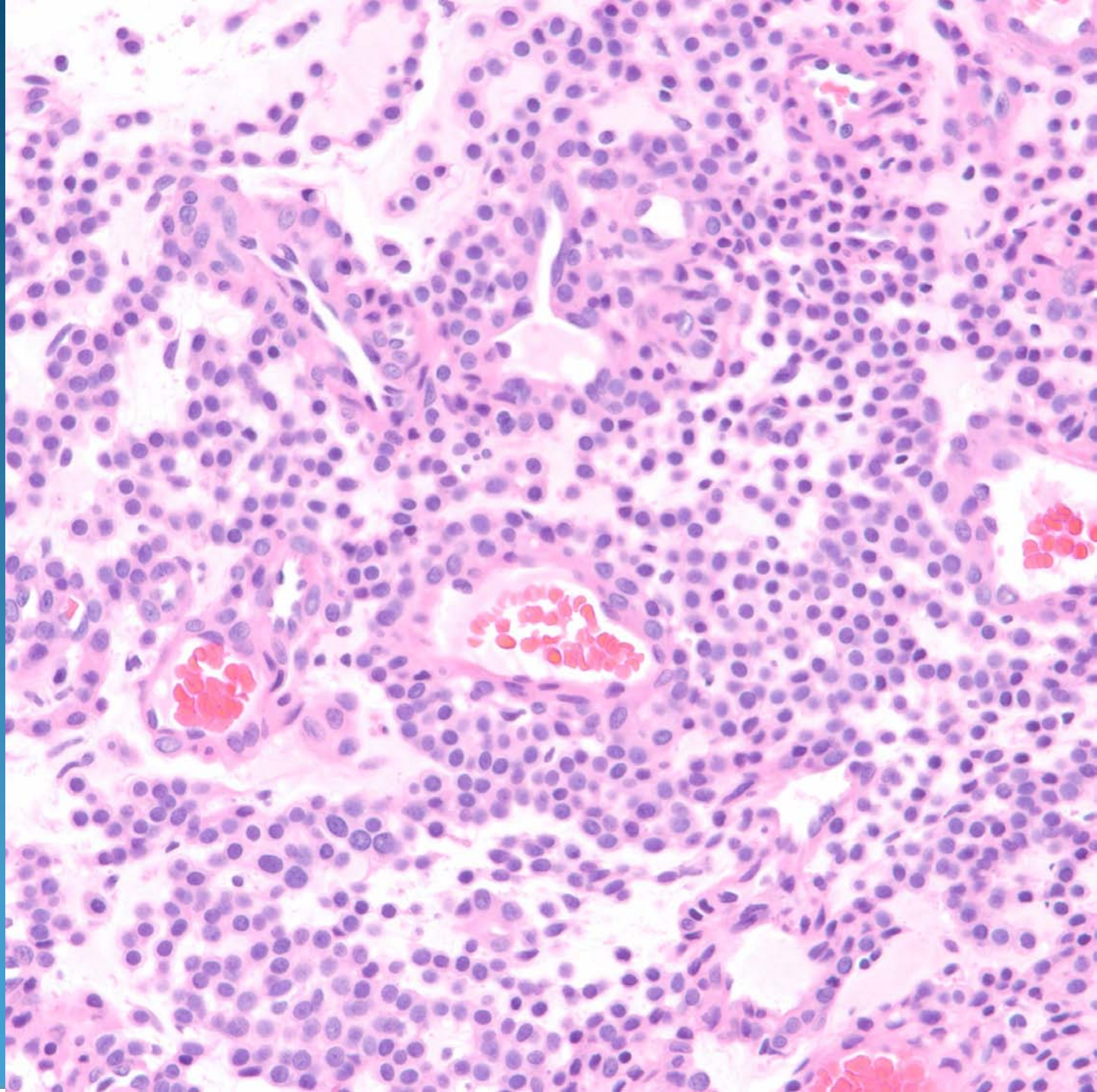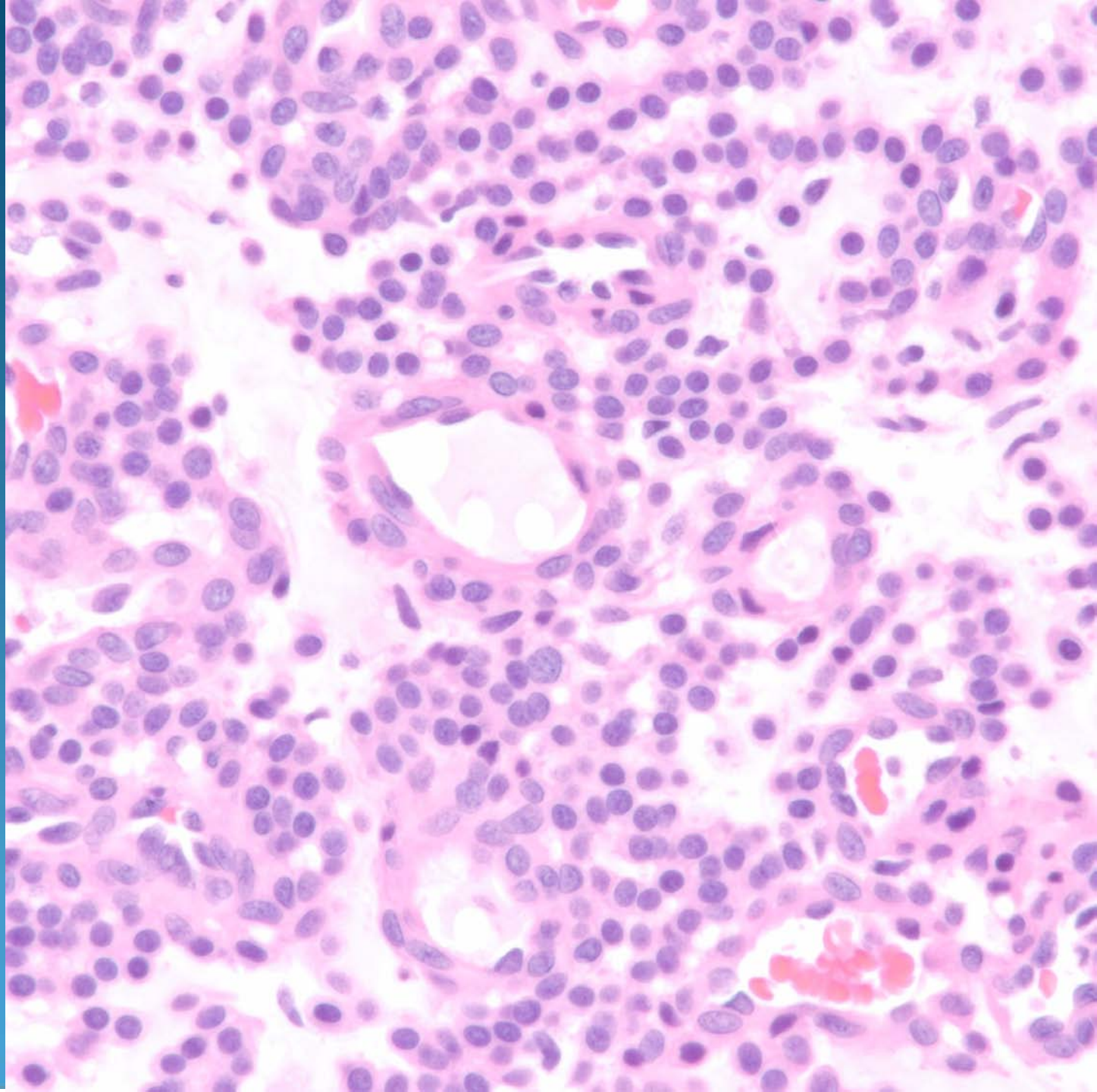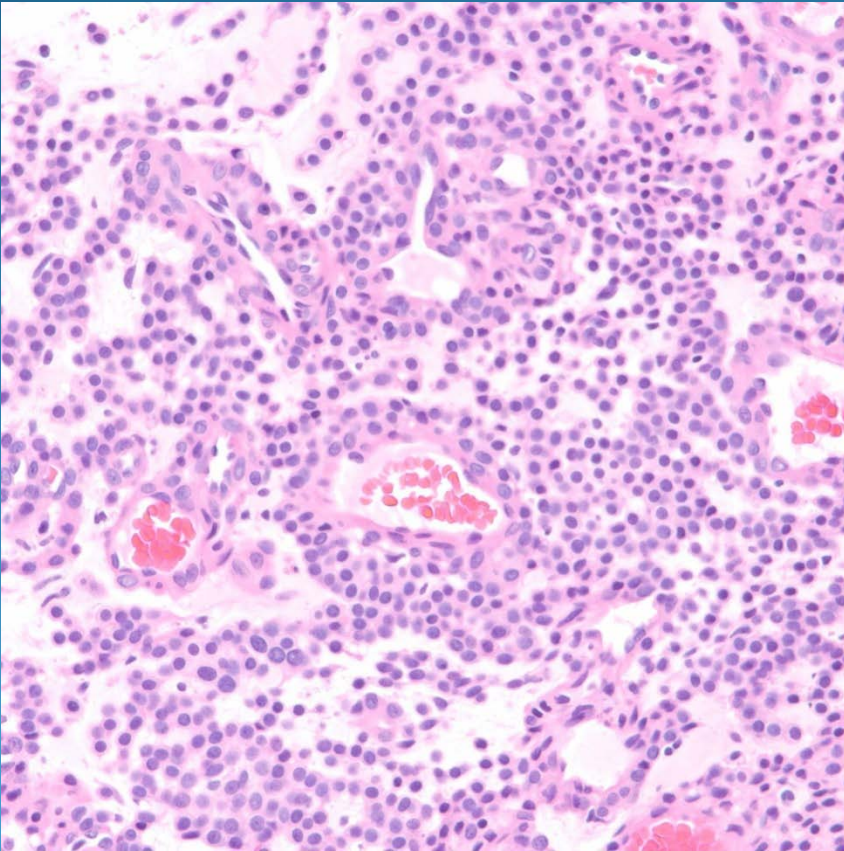


Glomangioma

Pearls



- Nodular and cellular dermal tumor with ectatic vascular spaces
- Round to oval cells with “fried egg” appearance
- Minimal to absent atypia